

**Ian Fisk's
Brachytherapy**

Outline

- **Background**
- **BRACHYTHERAPY**
- **Prerequisites**
- **Advantages**
- **Disadvantages**
- **Procedure**
- **Recovery**

Background

- 1999, 2000 PSA around 1.
- DRE late April 2002 by GP, irregularity noticed. (general check up etc) referred to Urologist
- June appointment with specialist, although he denied it later, he told us “it is probably cancer”
- Immediately started some research, **Internet**, through Carole Pinnock got Mr Phip (Prostate Health Improvement Program), plus book (Localised prostate cancer)

Background cont'd

- Biopsy late June 2002 (had to stir to get it done before proposed 5 week away date!)
- According to Urologist “I was way ahead of where he intended me to be” in regard to my research of Prostate Cancer and treatment options.
- I was fortunate to get the results in just a few days. After I was told my mouth was certainly dry!
- 3 of 7 samples cancerous, less than 10, 15 and 25 % volume of samples, Gleason 6 (3+3), Stage T2

Background cont'd

- Prostate Support Awareness (Adelaide) Meeting in July a few days after my Pca diagnosis, talk by Dr Stapleton!
- Bone Scan July 5, 2002. Nothing other than a few arthritis hot spots found.
- Had consultations with 3 different GPs, another Urologists, one Radiation Oncologist. (she recommended I was suitable for Brachytherapy).
- I was Leaning towards Brachytherapy.
- Had an appointment at Alfred Hospital with Radiation Oncologist and their Urologist.

Background cont'd

- Also had an appointment at Peter MacCallum Institute (as they had only done one or two Brachy procedures, I was not too impressed by their experience!)
- Decided to give Alfred Hospital a go.
- The Message from all, “There is no need to rush into a decision on treatment, Pca is a slowly growing cancer.”

BRACHYTHERAPY.

(Mono therapy) What is it?

- Brachytherapy is the Permanent implantation of radioactive pellets (Iodine-125) in the prostate to kill all prostate cells, especially the cancerous ones. i.e. the seeds are implanted and left in the prostate to radioactively decay. As they decay, their radiation cooks the prostate cells and hopefully not too much surrounding tissue such as the rectum and bladder!

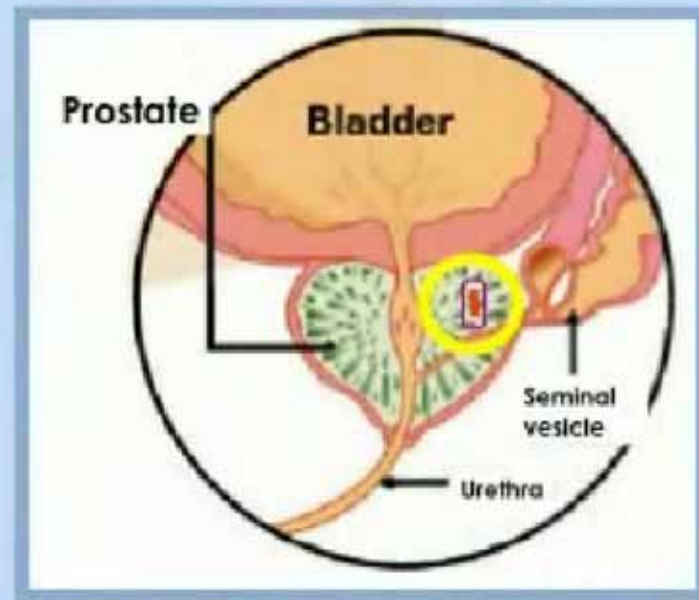
Iodine-125 seed brachytherapy



Radioactive
I-125 sealed in titanium seed



- ▶ High radiation dose to the prostate for cure
- ▶ Low dose to surrounding-
minimal side-effects



Prerequisites

- PSA 10 or less
- Gleason 6 or less
- Adequate Flow rate (scarring of the urethra can and does reduce the flow rate)
- Volume of Prostate not too big (if too big the pubic bone can restrict access to the whole gland for the purpose of implantation). Hormone treatment is sometimes given to reduce the size of the prostate.

Advantages

- Can be a once only Day Procedure, or at most one night in hospital.
- Results appear to be as good as RP for cure.
- Incontinence a rare side effect, impotence seems less likely than from a RP, reduction in penis size much less likely than that from RP.
- Faecal incontinence side effects rare.

Disadvantages

- Back in 2002 it was not available in Adelaide, only available in Melbourne, Sydney and Perth.
- Flow problems not unusual.
- Impotence possible, but may not appear until some time later.
- Only glow brightly in the dark for a month or so!!
Have to keep away (at least 2 meters) from children and pregnant women for at least two months, none on lap etc.
- Don't have a detailed biopsy of the prostate as after a RP, nor look/biopsy of lymph nodes.

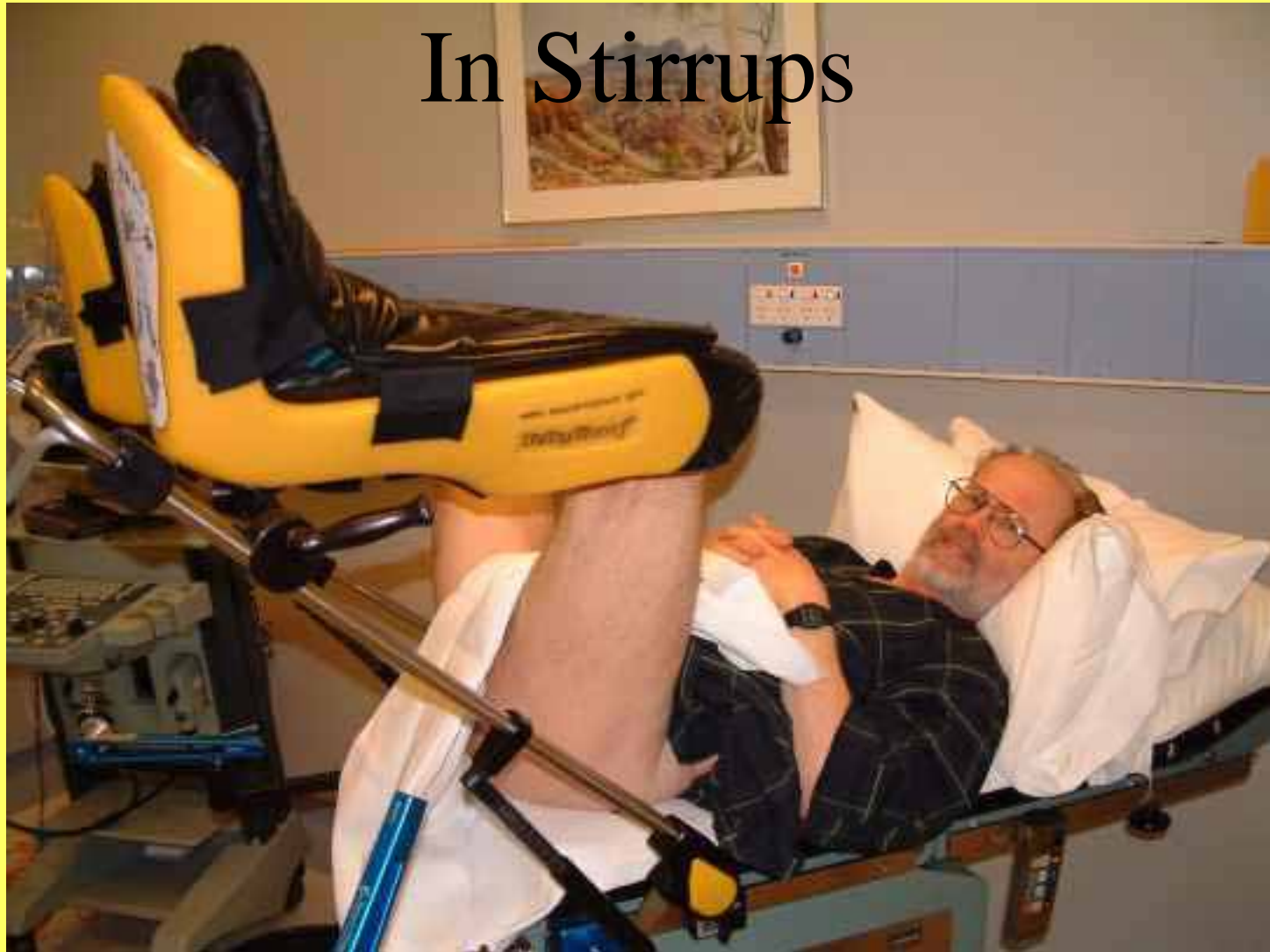Disadvantages (cont'd)

- Not supposed to ride a bike for 6 months after the procedure!
- Cost, after Medicare and Health Fund claims I was out of pocket by \$6,000.

Volume Study

- Probe up rectum, catheter up urethra (helps with imaging)
- From ultrasound study the shape and volume of the prostate is determined, from that the precise mapping of where the seeds are to be implanted is determined.

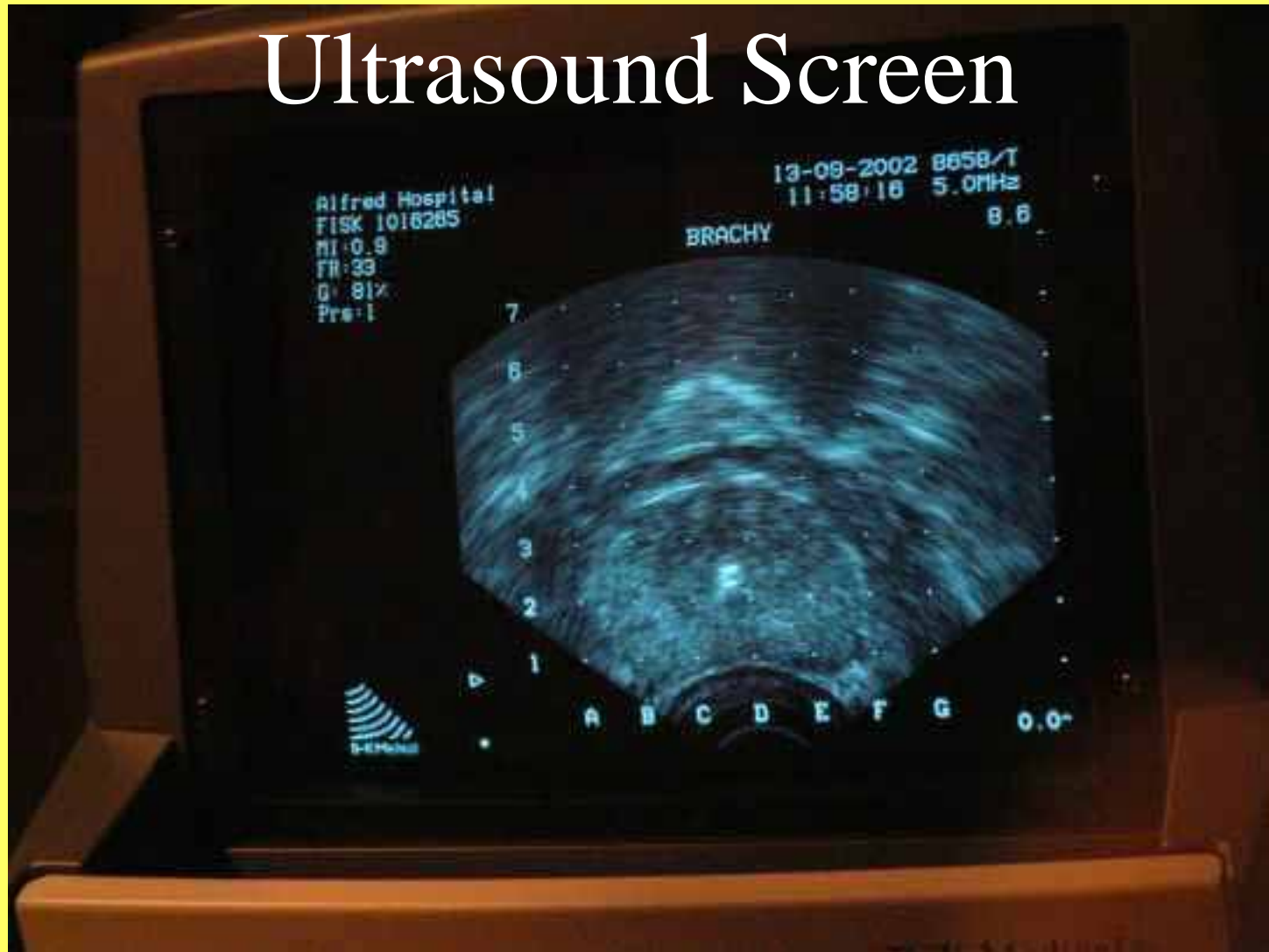In Stirrups



Dr about to insert Ultrasound Probe



Ultrasound Screen

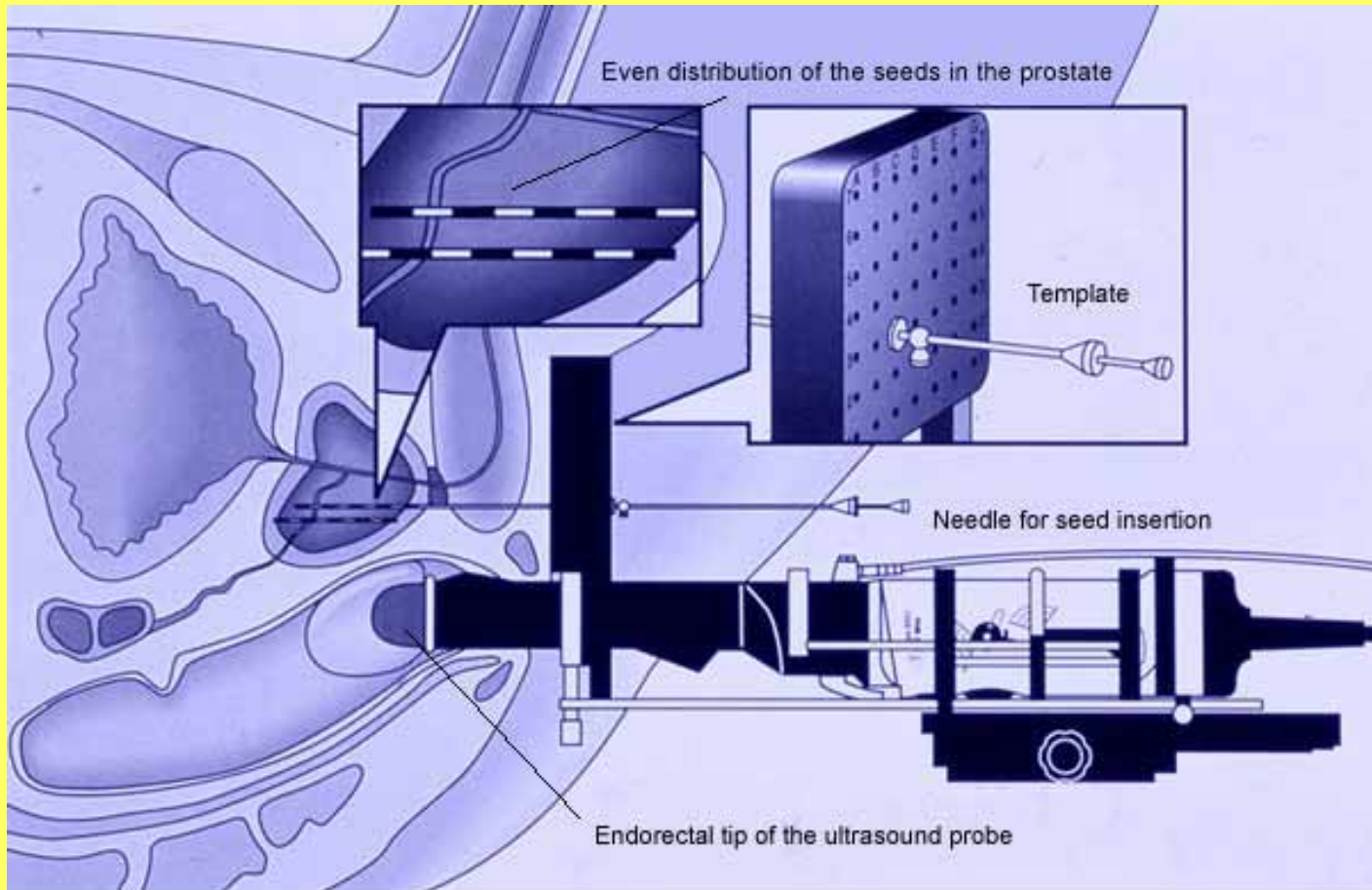


Implantation

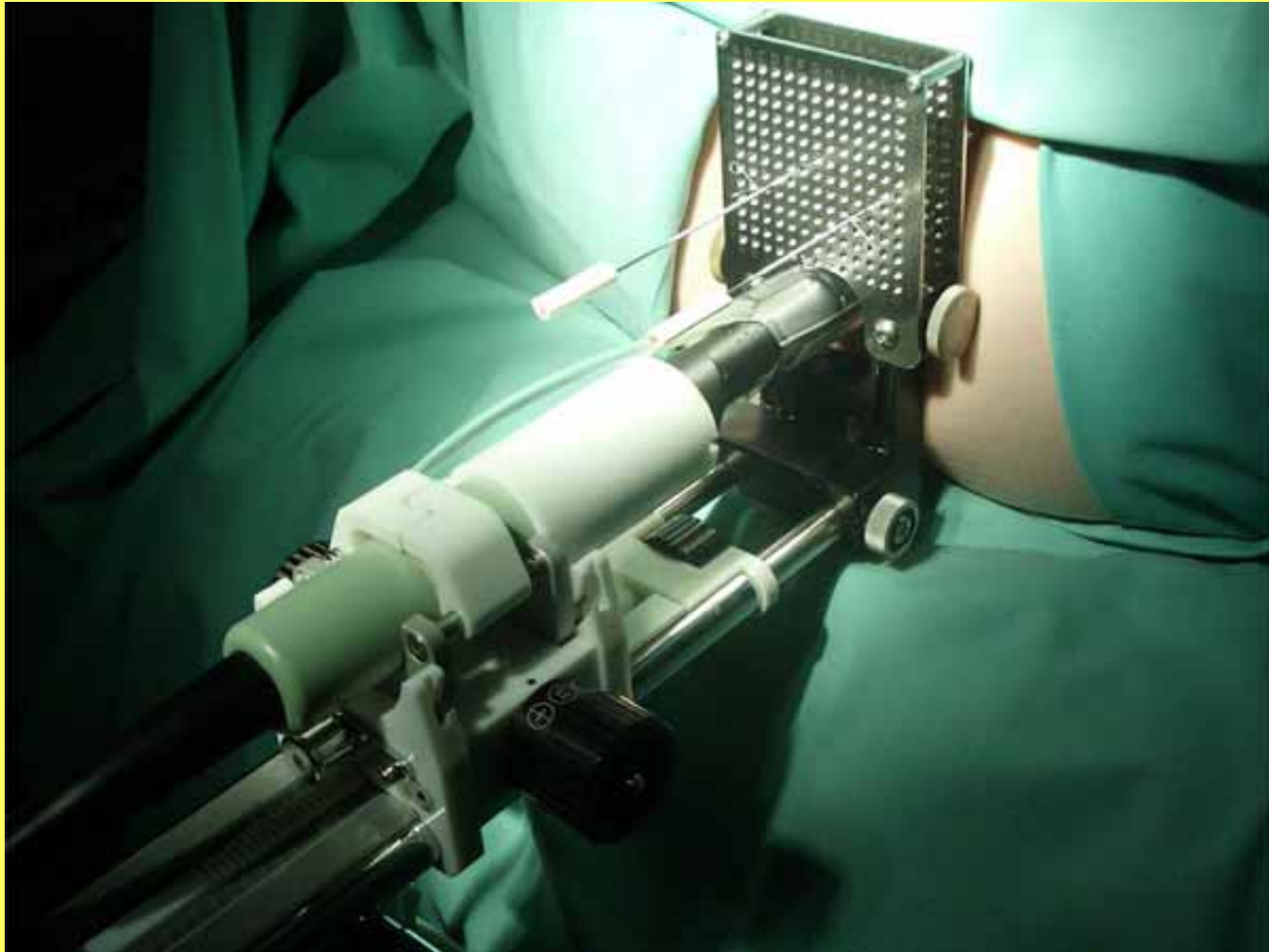- Pre procedure Diet – low residue, fluids and solids, eggs, cheese, plain white bread, no fibre etc
- 2 by enemas, Early check in, wait, decision regarding general or epidural
- epidural done
- Back in Stirrups, don't remember a lot! Slept through some, No Pictures
- Back in room by 11, catheter still in
- Ate lunch ok etc, lots to drink
- Catheter removed late afternoon

Procedure cont'd

- By evening I still could not empty bladder, so catheter re-inserted and had to spend the night in their “Medi Hotel” really just on 4th floor!
- Not a comfortable night attached to catheter.
- Catheter Out after 9 next morning
- Passed big clot of blood, then flow ok
- Back at Van Park by 1240 (bursting)



Transperineal insertion of radioactive seeds into the prostate under transrectal ultrasound guidance



Tea Strainer

- For a number of weeks, I had to check that no seeds had escaped into the urine stream!
- I had to pee through a tea strainer!
- Use condom etc



Follow Up

- CT Scan and Chest X-ray four weeks after implant plus PSA test. (Another trip to Melbourne)
- Check where actual seeds ended up and whether any have migrated to the lungs.
- Insertion and especially removal of catheter not pleasant, emptying bladder very painful for a few hours.
- Three weeks later went back to Melbourne for the results. (ok)

Recovery

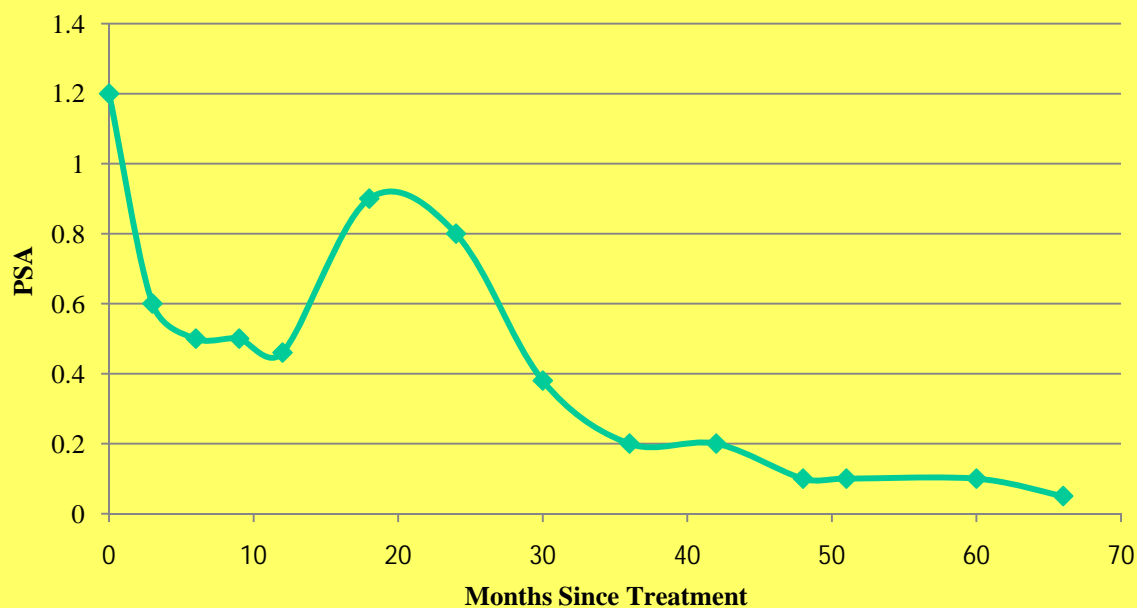
- Painful sitting, but had circular cushion that made sitting almost comfortable, had to use it for months after.
- Colourful bruising in the lower regions, won't show pictures!
- Drove back to Adelaide (except for a 100km) a couple of days after procedure.
- Walked ok right after, Played Badminton 1 week after procedure, windsurfed less than 2 weeks after.

Recovery cont'd

- Flow not the same as before, took Flowmax for around 5 months (not a cheap drug). Flow still slow, but can live with it.
- Bowel movements about the same.
- See Next Slide's Graph of my PSA verses time. A nadir of less than 0.05 seems to be considered very acceptable, but I will certainly keep an eye on it every 6 months.
- Other bits function ok! (but no seminal fluid at orgasm, just dribble!)

Graph of PSA changes

Ian Fisk's PSA



One final slide, a current picture of me!

That's all



Folks



Who brought the cat?